

+ Evidence in focus

Publication summary: Brownhill VR, et al. *Adv Wound Care* (2020)*

PICO[◇] Single Use Negative Pressure Wound Therapy System (sNPWT) increased wound closure, re-epithelialisation and maturity of granulation tissue compared with traditional NPWT (tNPWT) in a porcine model of wound healing

+ Plus points

Compared with tNPWT, PICO sNPWT had:



Greater reductions in wound area and more re-epithelialisation (at days 6 and 12 post injury; $p < 0.01$)



Increased maturity of granulation tissue and less wound bed damage at dressing change



Less compromised peri-wound skin

Overview

- Using an *in vivo* wound model (12 pigs), contralateral wounds were created (3cm diameter; 24 per group) and treated with either PICO sNPWT (no filler) or tNPWT (foam filler)
- PICO sNPWT was changed every 6 days and tNPWT was changed every 3 days
- Comparative assessments of wound area, re-epithelialisation and contraction were made at days 6 and 12
- Wound granulation, surface damage and peri-wound skin health were also assessed

Results

- Compared with tNPWT, PICO sNPWT had:
 - Significantly greater reductions in wound area at days 6 and 12 (Figure)
 - Increased re-epithelialisation at days 6 ($p < 0.01$) and 12 ($p < 0.001$)
 - Less wound edge hyperproliferation
 - Improved quality and maturity of granulation tissue (increased collagen deposition and matrix components)
 - Reduced wound surface damage with less noticeable bleeding upon dressing removal
- Wound bed inflammation was reduced with PICO sNPWT versus tNPWT
 - Trapped foam filler particles caused foreign body reactions (increased neutrophils, inflammatory cytokines and matrix metalloproteinases)
- With use of PICO sNPWT there was less disruption to skin around the wound, less peri-wound erythema and skin barrier function was less compromised than with tNPWT
- Peri-wound skin had less inflammation with use of PICO sNPWT than with tNPWT, which may help support a prohealing wound edge environment

Significantly greater wound area reductions with PICO sNPWT versus tNPWT

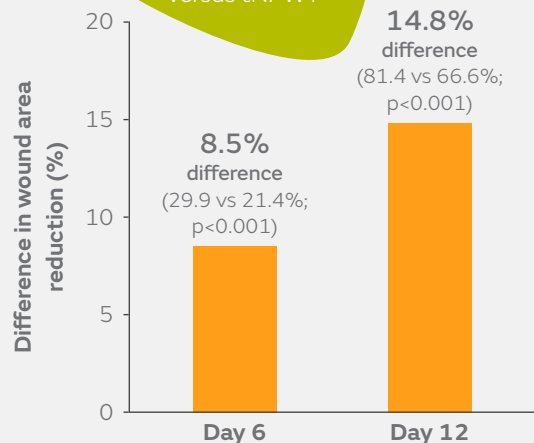


Figure. Difference in percentage change in wound area with PICO sNPWT versus tNPWT at days 6 and 12 post injury

Conclusions

Use of PICO sNPWT increased wound closure compared with tNPWT in this porcine model of wound healing; re-epithelialisation was faster, granulation tissue was more mature and peri-wound skin was less compromised.

Citation

*Brownhill VR, Huddleston E, Bell A, et al. Pre-clinical assessment of single-use negative pressure wound therapy during *in vivo* porcine wound healing. *Adv Wound Care*. 2020 Jul 7. [Epub ahead of print]. Available at: [Advances in Wound Care](#)

For detailed product information, including indications for use, contraindications, precautions and warnings, please consult the product's applicable Instructions for Use (IFU) prior to use.